

# TRIPOD—A new protocol for immediate loading

## Complete maxillary implant-supported prostheses

Author\_Dr Jean-Nicolas Hasson, Dr Jacques Hassid & Dominique Fricker, France

### \_Abstract

Complete maxillary implant-based bridgework is amongst the most challenging of restorative procedures. With TRIPOD, a new treatment protocol for planning and surgery, a radiographic template and a surgical guide are secured to three fixed reference points, such as natural teeth and previously placed dental implants. CT-based software enhances treatment by first validating the surgical guide, and then allowing chairside postmodification options. Open-flap surgery is initiated with sterile templates and impression trays. Implant sites are prepared with the surgical guide to a final depth with pilot drill and 2.8 mm diameter drill. Further site preparation involves implant-specific drills, piezosurgery and bone expanders. These developments improve the reliability of complex implant-based restorations.

### \_Introduction

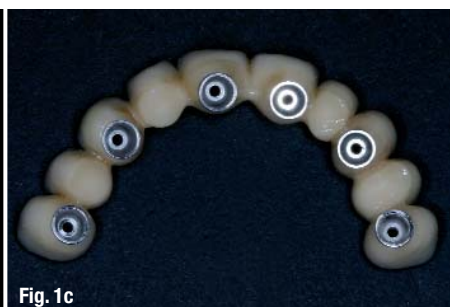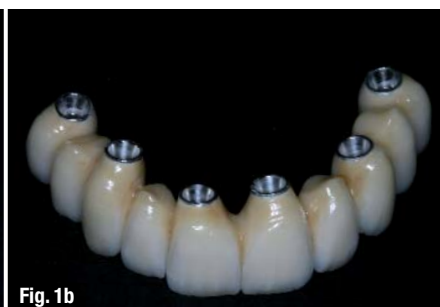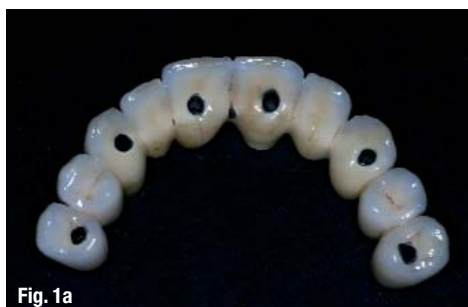Immediate loading of complete maxillary implant-supported bridgework is an increasing request by patients who have high aesthetic and functional demands and attach great importance to a neat appearance and their self-image. Since 1977, positive results have been obtained in immediate loading<sup>1,2</sup>, but these were limited to mandibular, bar-retained removable dentures. In 1997, Tarnow *et al.*<sup>3</sup> published a study

showing similar results for maxillary and mandibular full-arch, implant-supported bridgework, and, more recently, the focus has turned to the development of computer-based techniques for improved results. Highly sophisticated technical tools such as NobelGuide (Nobel Biocare) and the SAFE SurgiGuide® (Materialise Dental) have entered the market and related techniques such as All-on-4 (Nobel Biocare) are being promoted<sup>4,5</sup> to help meet patients' demands. All techniques are based on full maxillary bridgework with a screw-based retention. The screw-retained bridgework allows all procedures to be performed during the treatment, i.e. impression taking, bridge modification and repair for aesthetic or functional purposes.

Amongst the more challenging difficulties in carrying out such a therapy is implant positioning, especially for a single crown in the anterior region. Precise placement is essential in achieving good aesthetics, phonetics, function and cleanability. Most of the time, implant placement has to be within the limits of 0.5 mm (Fig. 1). Another factor to consider is the possible loss of alveolar bone after tooth extraction, leaving a minimal residual volume, and thereby increasing the difficulty of the procedure.

The positioning of implants depends on the guide's positional accuracy in a definitive place at the time of the surgery and on the accuracy of the guide itself. In

**Figs. 1a-c**\_Precision positioning of dental implants is mandatory for adequate abutment and screw placement.



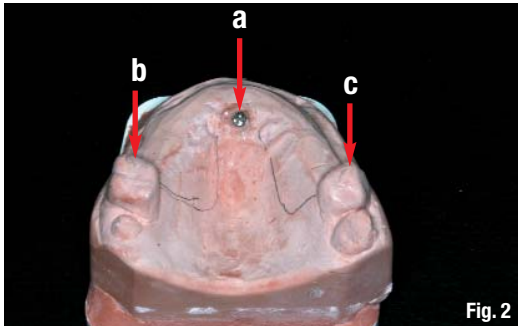


Fig. 2

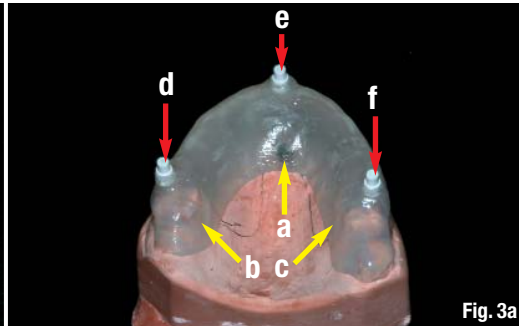


Fig. 3a

**Fig. 2\_** The Positioning TRIPOD is based on a temporary implant (a) and two residual teeth (b & c).

**Fig. 3a\_** Radiographic template fixed on the Positioning TRIPOD (a, b & c) with standardised X-ray opaque resin pins (d, e & f).

the case of NobelGuide, accurate positioning depends on the patient's ability to bite reproducibly and precisely, with even gingival thickness and consistency, and assumes that bone shows a similar degree of hardness at different screw-retention sites. Unfortunately, as recently reviewed by Schneider *et al.*<sup>6</sup> and detailed by Valente *et al.*<sup>7</sup>, the deviation between entry point and orientation consistently differs between the planned and actual position of the implants. This generally accounts for the results obtained by guides used in flapless surgery. Other failure factors may be related to poor cooling ability during the drilling procedure.<sup>8</sup>

As cited above, inaccuracies may arise from the positioning of the guide or of the patient, or be related to the radiological technique itself. In the case of flapless surgery, the position of the guide is conditioned by the thickness and consistency of the underlying soft tissue, as well as the patient's ability to bite precisely in a replicable manner. In addition, there is always some degree of patient movement during the CT scan, which can hardly be controlled, an inaccuracy termed a 'mechanical artefact'. Of course, any study performed on cadavers or models cannot reproduce this particular radiological aspect.<sup>9,10</sup> Other inaccuracies are related to the radiological equipment itself and include geometric, hardening and threshold artefacts. Geometric artefacts are related to the ability of software to reconstruct a 3-D space based on the serial addition of 2-D images that are filtered by the software.<sup>11,12</sup> Hardening artefacts are due to the different densities of adjacent objects. An X-ray beam is composed of individual photons with a range of energies. As the beam passes through an object, it becomes 'harder', that is, its mean energy increases because the lower-energy photons are absorbed more rapidly than higher-energy photons.<sup>13</sup> The last significant artefact, the digital artefact, is due to the segmentation masks that are used to obtain volumes. In order to obtain a mask, an interval of radiodensity is defined by choosing the Hounsfield values at both ends of the tissue(s) under interest. By using this method, an area of lower or greater density can be discarded and missed in the final volume. This may be particularly true when digitally producing a surgical template based on hard or soft tissue. Finally, images produced by available tech-

niques are too unreliable to be used directly for this type of treatment. We propose a new protocol in this article with the aim of reducing inaccuracies in terms of reliability, aesthetics and function.

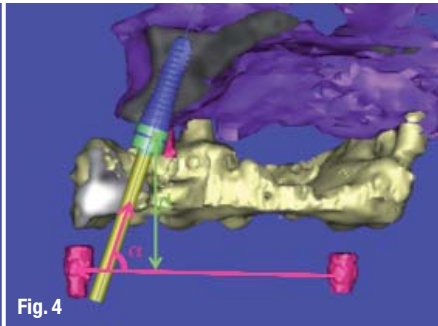
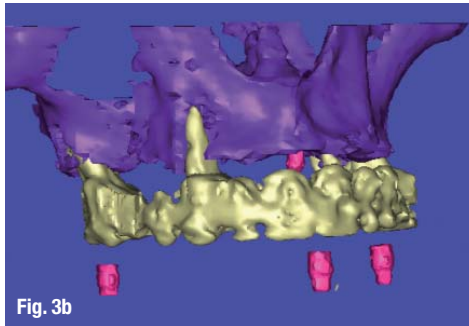
#### *TRIPOD: Description of a new clinical technique*

Initially, a treatment plan is performed to adequately evaluate a case, propose alternate solutions and decide whether the patient is a suitable candidate for a fully implant-supported maxillary bridge. This requires a first assessment that includes a possible wax-up and a radiographic stent for visualising the crown position on the CT scan, as well as an evaluation of a potential need for bone- and soft-tissue augmentation procedures. Patients often present with their own cement-retained bridgework on natural teeth in place that, when adequate, may be used as a reference guide for implant placement. It is essential to evaluate the implant site within the maxillary bone precisely. In order to perform these measurements, a Positioning TRIPOD and a Computing TRIPOD need to be determined.

The term 'Positioning TRIPOD' is used to denote the selected pre-existing three fixed points (Fig. 2) in the mandible or maxilla, which can be based on:

- \_teeth that are stable enough to support the surgical guide during surgery;
- \_implants placed in posterior areas;
- \_temporary mini-implants that will be removed at the end of surgery.

The choice of appropriate bases for the Positioning TRIPOD is critical for its accuracy. Owing to its compressibility, soft gingival tissue has to be avoided. Problems with remaining teeth may arise due to advanced periodontal disease causing excessive mobility. In some cases, temporary mini-implants are used, but often the amount of maxillary residual bone is so reduced that these implants only interfere with definitive implant placement. Nevertheless, they may be useful when no other alternative is available. Anecdotal cases in which there is sufficient bone for temporary and definitive implants at the same time have been reported, but are rare. The best choice is to use posteriorly placed implants before inserting anterior implants. In this case, an extremely precise positioning



**Fig. 3b** The Computing TRIPOD.

**Fig. 4** The position of standardised X-ray opaque resin pins allows the calculation of implant coordinates.

**Fig. 5a** The drill sleeves being placed in the radiographic template with the transfer table.

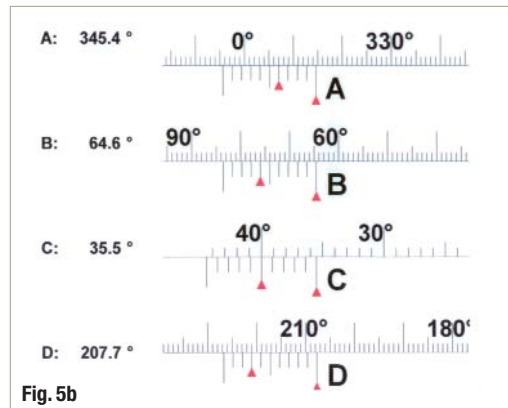
is not required since the large volume of the corresponding teeth provides some degree of freedom to the laboratory technician designing the prostheses. These posterior areas often require some bone reconstruction (such as sinus lift or onlay bone grafts), thereby prolonging time to loading. The corresponding implants will then ensure not only the most precise positioning for radiographic templates and surgi-

reference pins is detected by the software, building the Computing TRIPOD (Fig. 3b), and used to calculate the implant coordinates (Fig. 4). This data is then set in the transfer table (Fig. 5a) to place the drill sleeves accordingly and transfer the radiographic template into a surgical guide (Fig. 5b).

Some days prior to the full-arch surgery, once an adequate TRIPOD has already been planned and initial implants placed, an initial impression (Fig. 6) will be taken for the model to prepare the impression tray, occlusal guide, surgical guide from the radiographic template, as well as the provisional prostheses. The surgical guides are produced in sterilisable resin with radiopaque sleeves (DêPlaque). Special attention is given to the impression tray that will extend to all maxillary surfaces, but room for the impression material is exclusively limited to the planned implant sites. They must be ready at the time of surgery.

On the day of the surgery, the practitioner begins by reducing all remaining crowns that would interfere with the surgical guide, which is then placed on teeth or preferably screwed onto previously placed implants forming the Positioning TRIPOD (Fig. 7). A CT is performed to verify all drilling sites. If any modification has to be done, there is still time to adjust the drill sleeves to adequate positions and to re-sterilise the guide.

The next step is the transfer of the occlusion to the articulator. Usually an occlusion guide is engineered before surgery and screwed into an adequate position. It is then adjusted and some silicone material is added



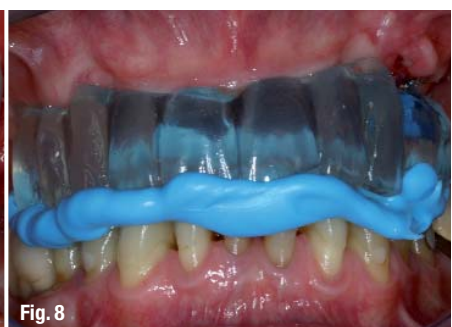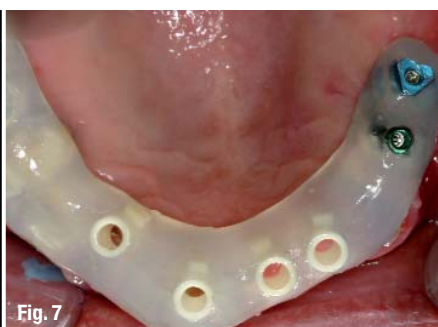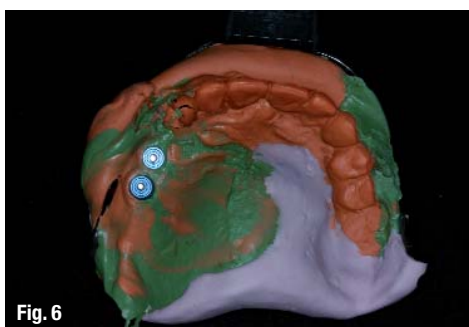
**Fig. 5b** The implant coordinates for the transfer table.

cal guides, but also for the occlusal guide and impression tray, since all these parts will be screw-connected to these previously placed and osseointegrated implants. In order to transfer the planned implant position from the planning software to the surgical guide, a Computing TRIPOD is necessary. This Computing TRIPOD is made with three SKYplanX reference pins (Bredent) placed on the radiographic template with the reference plate (Fig. 3a). The patient is scanned with the radiographic template fixed on the Positioning TRIPOD. The position of the standardised X-ray opaque

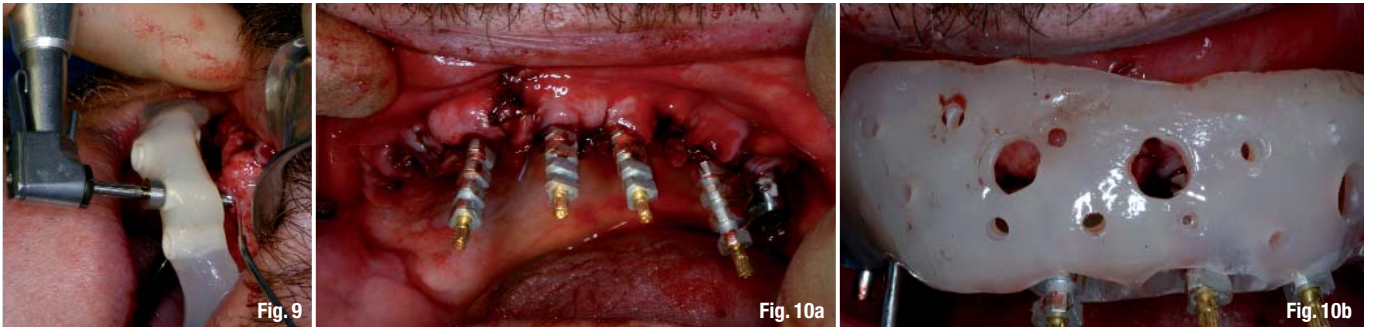
**Fig. 6** Initial impression of two initially placed implants.

**Fig. 7** Surgical guide placed on teeth and screwed onto previously placed implants forming the Positioning TRIPOD.

**Fig. 8** Occlusal guide screwed onto posterior implants.







to ensure a perfect bite (Fig. 8). The transfer is made to the articulator before starting surgery. It is sometimes possible to retain a molar with compromised prognosis until the end of definitive prosthesis, thereby keeping a reference point of initial occlusion.

When all materials are sterile, surgery can be initiated under the usual conditions. The flap is raised, the remaining teeth planned for extraction are removed and the surgical guide is placed on teeth or screwed onto implants. Holes of 2.0 and 2.8 mm are drilled through the sleeves using the VECTOdrill™ (Thommen Medical) with a smaller tip fitting in and following the prepared drill hole. Control of the depth is visual, since depth marks on the drills can be easily seen on the facial aspect of the surgical guide. Speed and torque are according to the manufacturer's instructions. Cooling is performed on the facial side (Fig. 9); the flap is maintained properly by the guide on the palatal side. Once the drilling has been completed, the surgical guide is removed and the last step of implant site preparation is done using implant-specific drills, bone spreaders or piezosurgery inserts. The choice of the implant relies not only on the diameter, but also on the implant length and profile to achieve the best possible implant stability. Implants with advanced surface technology, providing additional security in the early healing phase such as the super-hydrophilic Thommen implant lines SPI®ELEMENT (cylindrical profile) and SPI®CONTACT (conical-cylindrical profile) with INICELL® (Thommen Medical), are preferred. In order to perform immediate loading, the implant should be inserted with a minimum torque of 25 Ncm. If the bone provides poor primary stability, then a two-stage approach is required to ensure proper osseointegration

before placing the prostheses. SPI®VARIOmulti abutments (Thommen Medical) are connected to the implants by selecting proper width, height and angulation. Next, impression copings are connected to the SPI®VARIOmulti abutments and bone-grafting material such as BioOss® (Geistlich) is then spread on the facial bone in order to avoid facial bone resorption.<sup>14</sup> All synthetic bone graft material is covered by a thin and long-lasting membrane such as Remotis® membrane (Thommen Medical) and flaps are sutured with particular attention to ensuring wound closure.

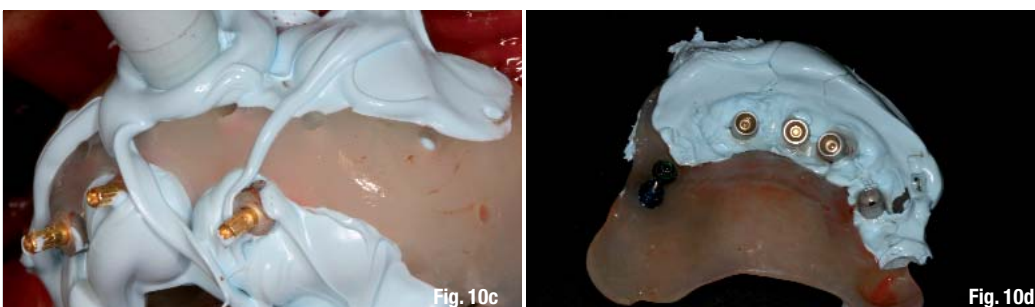
The impression tray is connected to the initially placed implants and silicone material is injected into the tray around implant transfers where room has been preserved for the impression material (Fig. 10). Once the impression tray has been removed, protective caps are positioned on the SPI®VARIOmulti abutments in order to maintain gingival spacing during the last laboratory prosthetic phase. A panoramic X-ray is performed to ensure proper positioning of implants and abutments, and to ensure that no radiopaque sterile silicone material remains.

The maxillary plaster model is trimmed to leave space for abutment analogues and plaster is poured to fill this open space after the impression tray has been secured to the trimmed model (Fig. 11). The modified model simultaneously shows two parts: the first part corresponding to the initial impression and the other corresponding to the second impression (Fig. 12). The provisional prostheses are fitted to the model and occlusion is validated. When this laboratory phase is over, the protective caps are removed, and the prostheses are screwed into position (Figs. 13a & b). If well done,

**Fig. 9** Adequate cooling and visualisation during drilling.


**Fig. 10a** Second impression taking at time of surgery with Thommen impression copings on SPI®ELEMENT implants.

**Fig. 10b** Placing of the individualized open tray.

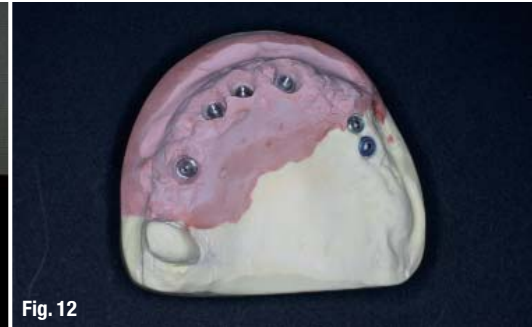

**Figs. 10c & d** Injection of silicone material and final second impression.

**Fig. 11** Second impression secured to reduced initial model mounted in the articulator.



**Fig. 12** Modified model: the yellow part corresponds to the initial impression; the pink part was poured at the time of surgery.



occlusal adjustments should be minimal, even perhaps none being required. Temporary caps on SPI®VARIO-multi are filled with temporary light-cured material to close the screw channel and the patient is advised to treat the temporary bridgeworks in a gentle manner.

Sutures are removed after ten days. The aesthetics is re-evaluated three months after surgery, before initiating the final prostheses, owing to subsequent loss of tissue volume. Additional temporary bridgework is often required to test that the final aesthetic will be adequate before proceeding with the definitive prostheses.

### Discussion

There are multiple technical benefits of the TRIPOD procedure. Precision implant placement is achieved by removing positional and mechanical artefacts, particularly when the actual surgical guide is screwed onto stable implants. In other words, there is no movement evoked by a bite variation or tissue differences, and if the patient moves during the CT scan, the guide moves with the anatomical structures. However, there is no way to conquer geometric, hardening or digital artefacts. There is still room for a small degree (< 1 mm) of freedom in implant placement and, if necessary, final correction can be done after the initial drilling with the 2.8 mm drill. This results in a maximum freedom of approximately 0.7 mm in diameter for a final implant site with a diameter of 3.5 mm. However, considering that the last drill at the centre is just half of this value, this freedom corresponds radially to 0.35 mm, providing an opportunity to adapt the implant site preparation to

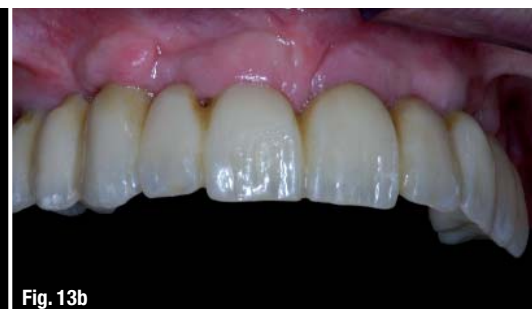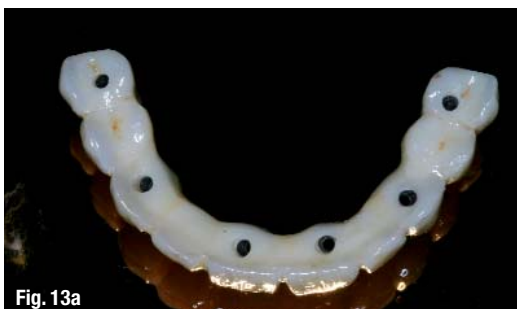anatomical conditions slightly. This distance of 0.35 mm is sufficiently important to become particularly significant for leaving some buccal bone, but it is still small enough to be handled by the dental technician for ideal prosthetic screw placement. Nevertheless, the initial implant placement cannot exceed this limit, which evokes the necessity of very precise initial drilling and, at the time, an additional step to verify that the surgical guide is actually suitable for use.

Compared with flapless techniques, open flap surgery not only allows the visual opportunity for controlling bone site preparation, but also retains precious keratinised tissue that is important for both marginal tissue stability and volume. The patient's reaction to this procedure, with its associated pain and discomfort, still has to be examined in future studies.

Another benefit of this procedure is that sterility is maintained throughout the surgery, since all materials used can be sterilised, which is not the case with common guides such as NobelGuide or the SAFE SurgiGuide®, which are both made of a stereolithic resin and are currently not capable of undergoing sterilisation. In addition, the precision of the procedure allows the impression tray to remain unmodified—and thus sterile—throughout the surgery.

Yong and Moy<sup>8</sup> state that implant loss was probably primarily related to the absence of proper cooling ability when using NobelGuide, since most of the late implant failures involved long implants in cases in which the guide was used directly at the gingival contact. Indeed, only the rear part of the drill (thus far

**Figs. 13a & b** Initial provisional bridgework in place.



from the tip) can be cooled efficiently, and thereby probably makes the cooling procedure ineffective. In contrast, during the described TRIPOD procedure, the guide is placed on the gingiva at the time of fabrication, leaving an open space for cooling at the time of the open flap surgery. In addition, the bone becomes visible, which allows the practitioner to visualise the depth marks of the drill right at the crestal ridge, making the instrumentation less expensive and easier, as no special drill with mechanical depth limitation is required. Site preparation may be modified by using piezoelectric bone surgery, since this device can grind bone on a particular wall from the previous drilling, in contrast to conventional drilling, which grinds all walls from the previous drilling, with a preference for softer tissue and resulting in facial bone perforation. In some situations, one might also consider changing from drills to bone spreaders; this would compact the surrounding bone and provide additional stability to the corresponding implant. Finally, the implant could be adapted to a recipient site by choosing an appropriate diameter, length and even the profile (e.g. from conical to conical-cylindrical) once site preparation has almost been completed.

The previously placed implants not only add useful precision to implant site preparation with the guide, but also provide essential stability to immediately loaded bridgework in an area where stability in the initial healing phase is probably vital to success. Most patients are already older, with a history of periodontitis, tooth loss and associated impaired medical conditions, and possibly reduced healing capacity. Therefore, it is of major interest to be able to assess the healing capacity by the stability of previously placed implants, before undergoing and performing a full-arch maxillary bridge immediately loaded on implants, preferably with advanced surface technology. Most of the cases require some sort of bone grafting in the posterior areas and this technique leaves time for initial healing before occlusal loading. In fact, some of the implants would be subjected to immediate loading, while others—the most critical in terms of bone volume availability and location—could be loaded according to a classical schedule. This should be considered when making a comparison with other procedures with surgical guides.

The INICELL® surface found on Thommen Medical implants showed more bone-to-implant contact and a higher removal torque at two weeks than unconditioned implants did.<sup>15</sup> This aspect should be particularly useful in the early stages of healing and providing additional security in this crucial phase. In addition, this company provides implants of various diameters, length and profiles to satisfy various implant site requirements and which provide the best possible stability.

## \_ Conclusion

The TRIPOD protocol is based on our latest clinical experience. It utilises CBCT, as well as the vast developments of implant placement planning software and computer-guided implant dentistry. The efficiency of the technique must still be validated by analysis of implant survival in different clinical environments, specifically investigating adequate positioning between planned and final implant position, and the need to verify the surgical guide after the learning process has been completed. Finally, a study on patients' satisfaction with the procedure in terms of pain and aesthetic outcome needs to be performed. We must still determine whether the benefits of open flap surgery in combination with surgical guides outweigh the related discomfort and pain for the patient: does this pose a major problem for patients, are the final aesthetics improved by preserving keratinised tissue, and does such a technique fulfil expectations, considering that bone volume loss is often difficult to limit in these areas?

The proposed TRIPOD procedure is certainly more labour-intensive than current flapless guide systems, since a flap has to be raised and no definitive prosthesis is placed right after surgery. Nevertheless, it is also more versatile because maintaining or increasing bone volume is considered in the treatment plan and is adapted to the individual situations. The risk of failure is considerably reduced by connecting immediately placed implants to osseointegrated implants. Furthermore, this procedure allows using the last millimetre, as typical cases show reduced bone volume and require the widest and longest implants within anatomical restrictions. Although knowledge and close collaboration with the laboratory technician are required, this procedure adds fundamental security and predictability for success, and will certainly be adapted to different practice situations and one-day procedures.

*Editorial note: A list of references is available from the publisher.*

## \_ contact

## implants

### Dr Jean-Nicolas Hasson

5 Rue du Werkhof  
68100 MULHOUSE  
France

Tel.: +33 389 458984  
Fax: +33 389 563112

E-mail: hasson@hrnet.fr